

SUMMARY OF PRODUCT CHARACTERISTICS

▼ This medicinal product is subject to additional monitoring. This will allow quick identification of new safety information. Healthcare professionals are asked to report any suspected adverse reactions. See section 4.8 for how to report adverse reactions.

1 NAME OF THE MEDICINAL PRODUCT

Byooviz 10 mg/ml solution for injection in pre-filled syringe

2 QUALITATIVE AND QUANTITATIVE COMPOSITION

One ml contains 10 mg ranibizumab*. One pre-filled syringe contains 0.165 ml, equivalent to 1.65 mg ranibizumab. This provides a usable amount to deliver a single dose of 0.05 ml containing 0.5 mg ranibizumab.

*Ranibizumab is a humanised monoclonal antibody fragment produced in *Escherichia coli* cells by recombinant DNA technology.

Excipient with known effect

This medicine contains 0.0165 mg of polysorbate 20 (E 432) in each pre-filled syringe (0.165 ml) which is equivalent to 0.005 mg/0.05 ml. Polysorbates may cause allergic reactions.

For the full list of excipients, see section 6.1.

3 PHARMACEUTICAL FORM

Solution for injection.

Clear, colourless to pale yellow aqueous solution.

4 CLINICAL PARTICULARS

4.1 Therapeutic indications

Byooviz is indicated in adults for:

- The treatment of neovascular (wet) age-related macular degeneration (AMD)
- The treatment of visual impairment due to diabetic macular oedema (DME)
- The treatment of proliferative diabetic retinopathy (PDR)
- The treatment of visual impairment due to macular oedema secondary to retinal vein occlusion (branch RVO or central RVO)
- The treatment of visual impairment due to choroidal neovascularisation (CNV)

4.2 Posology and method of administration

Byooviz must be administered by a qualified ophthalmologist experienced in intravitreal injections.

Posology

Adults

The recommended dose for Byooviz in adults is 0.5 mg given as a single intravitreal injection. This corresponds to an injection volume of 0.05 ml. The interval between two doses injected into the same eye should be at least four weeks.

Treatment in adults is initiated with one injection per month until maximum visual acuity is achieved and/or there are no signs of disease activity i.e. no change in visual acuity and in other signs and symptoms of the disease under continued treatment. In patients with wet AMD, DME, PDR and RVO, initially, three or more consecutive, monthly injections may be needed.

Thereafter, monitoring and treatment intervals should be determined by the physician and should be based on disease activity, as assessed by visual acuity and/or anatomical parameters.

If, in the physician's opinion, visual and anatomic parameters indicate that the patient is not benefiting from continued treatment, Byooviz should be discontinued.

Monitoring for disease activity may include clinical examination, functional testing or imaging techniques (e.g. optical coherence tomography or fluorescein angiography).

If patients are being treated according to a treat-and-extend regimen, once maximum visual acuity is achieved and/or there are no signs of disease activity, the treatment intervals can be extended stepwise until signs of disease activity or visual impairment recur. The treatment interval should be extended by no more than two weeks at a time for wet AMD and may be extended by up to one month at a time for DME. For PDR

and RVO, treatment intervals may also be gradually extended, however there are insufficient data to conclude on the length of these intervals. If disease activity recurs, the treatment interval should be shortened accordingly.

The treatment of visual impairment due to CNV should be determined individually per patient based on disease activity. Some patients may only need one injection during the first 12 months; others may need more frequent treatment, including a monthly injection. For CNV secondary to pathologic myopia (PM), many patients may only need one or two injections during the first year (see section 5.1).

Ranibizumab and laser photocoagulation in DME and in macular oedema secondary to BRVO

There is some experience of ranibizumab administered concomitantly with laser photocoagulation (see section 5.1). When given on the same day, ranibizumab should be administered at least 30 minutes after laser photocoagulation. Ranibizumab can be administered in patients who have received previous laser photocoagulation.

Ranibizumab and verteporfin photodynamic therapy in CNV secondary to PM

There is no experience of concomitant administration of ranibizumab and verteporfin.

Special populations

Hepatic impairment

Ranibizumab has not been studied in patients with hepatic impairment. However, no special considerations are needed in this population.

Renal impairment

Dose adjustment is not needed in patients with renal impairment (see section 5.2).

Elderly

No dose adjustment is required in the elderly. There is limited experience in patients older than 75 years with DME.

Paediatric population

The safety and efficacy of ranibizumab in children and adolescents below 18 years of age have not been established. Available data in adolescent patients aged 12 to 17 years with visual impairment due to CNV are described in section 5.1 but no recommendation on a posology can be made.

Method of administration

Single-use pre-filled syringe for intravitreal use only. The pre-filled syringe contains more than the recommended dose of 0.5 mg. The extractable volume of the pre-filled syringe is not to be used in total. The excess volume should be expelled prior to injection. Injecting the entire volume of the pre-filled syringe could result in

overdose. To expel the air bubble along with the excess medicinal product, carefully push the plunger rod until the upper edge below the dome of the rubber stopper is aligned with the 0.05 ml translucent dose mark.

Byooviz should be inspected visually for particulate matter and discoloration prior to administration. For information on preparation of Byooviz, see section 6.6.

The injection procedure should be carried out under aseptic conditions, which includes the use of surgical hand disinfection, sterile gloves, a sterile drape and a sterile eyelid speculum (or equivalent) and the availability of sterile paracentesis (if required). The patient's medical history for hypersensitivity reactions should be carefully evaluated prior to performing the intravitreal procedure (see section 4.4). Adequate anaesthesia and a broad-spectrum topical microbicide to disinfect the periocular skin, eyelid and ocular surface should be administered prior to the injection, in accordance with local practice.

For information on preparation of Byooviz, see section 6.6.

In adults, the injection needle should be inserted 3.5-4.0 mm posterior to the limbus into the vitreous cavity, avoiding the horizontal meridian and aiming towards the centre of the globe. The injection volume of 0.05 ml is then delivered; a different scleral site should be used for subsequent injections.

4.3 Contraindications

Hypersensitivity to the active substance or to any of the excipients listed in section 6.1.

Patients with active or suspected ocular or periocular infections.

Patients with active severe intraocular inflammation.

4.4 Special warnings and precautions for use

Traceability

In order to improve the traceability of biological medicinal products, the name and the batch number of the administered product should be clearly recorded.

Intravitreal injection-related reactions

Intravitreal injections, including those with ranibizumab, have been associated with endophthalmitis, intraocular inflammation, rhegmatogenous retinal detachment, retinal tear and iatrogenic traumatic cataract (see section 4.8). Proper aseptic injection techniques must always be used when administering ranibizumab. In addition, patients should be monitored during the week following the injection to permit early

treatment if an infection occurs. Patients should be instructed to report any symptoms suggestive of endophthalmitis or any of the above mentioned events without delay.

Intraocular pressure increases

In adults, transient increases in intraocular pressure (IOP) have been seen within 60 minutes of injection of ranibizumab. Sustained IOP increases have also been identified (see section 4.8). Both intraocular pressure and the perfusion of the optic nerve head must be monitored and managed appropriately.

Patients should be informed of the symptoms of these potential adverse reactions and instructed to inform their physician if they develop signs such as eye pain or increased discomfort, worsening eye redness, blurred or decreased vision, an increased number of small particles in their vision, or increased sensitivity to light (see section 4.8).

Bilateral treatment

Limited data on bilateral use of ranibizumab (including same-day administration) do not suggest an increased risk of systemic adverse events compared with unilateral treatment.

Immunogenicity

There is a potential for immunogenicity with ranibizumab. Since there is a potential for an increased systemic exposure in subjects with DME, an increased risk for developing hypersensitivity in this patient population cannot be excluded. Patients should also be instructed to report if an intraocular inflammation increases in severity, which may be a clinical sign attributable to intraocular antibody formation.

Concomitant use of other anti-VEGF (vascular endothelial growth factor)

Ranibizumab should not be administered concurrently with other anti-VEGF medicinal products (systemic or ocular).

Withholding ranibizumab in adults

The dose should be withheld and treatment should not be resumed earlier than the next scheduled treatment in the event of:

- a decrease in best-corrected visual acuity (BCVA) of ≥ 30 letters compared with the last assessment of visual acuity;
- an intraocular pressure of ≥ 30 mmHg;
- a retinal break;
- a subretinal haemorrhage involving the centre of the fovea, or, if the size of the haemorrhage is $\geq 50\%$, of the total lesion area;
- performed or planned intraocular surgery within the previous or next 28 days.

Retinal pigment epithelial tear

Risk factors associated with the development of a retinal pigment epithelial tear after anti-VEGF therapy for wet AMD and potentially also other forms of CNV, include a large and/or high pigment epithelial retinal detachment. When initiating ranibizumab therapy, caution should be used in patients with these risk factors for retinal pigment epithelial tears.

Rhegmatogenous retinal detachment or macular holes in adults

Treatment should be discontinued in subjects with rhegmatogenous retinal detachment or stage 3 or 4 macular holes.

Populations with limited data

There is only limited experience in the treatment of subjects with DME due to type I diabetes. Ranibizumab has not been studied in patients who have previously received intravitreal injections, in patients with active systemic infections, or in patients with concurrent eye conditions such as retinal detachment or macular hole. There is limited experience of treatment with ranibizumab in diabetic patients with an HbA1c over 108 mmol/mol (12%) and no experience in patients with uncontrolled hypertension. This lack of information should be considered by the physician when treating such patients.

There are insufficient data to conclude on the effect of ranibizumab in patients with RVO presenting irreversible ischaemic visual function loss.

In patients with PM, there are limited data on the effect of ranibizumab in patients who have previously undergone unsuccessful verteporfin photodynamic therapy (vPDT) treatment. Also, while a consistent effect was observed in subjects with subfoveal and juxtafoveal lesions, there are insufficient data to conclude on the effect of ranibizumab in PM subjects with extrafoveal lesions.

Systemic effects following intravitreal use

Systemic adverse events including non-ocular haemorrhages and arterial thromboembolic events have been reported following intravitreal injection of VEGF inhibitors.

There are limited data on safety in the treatment of DME, macular oedema due to RVO and CNV secondary to PM patients with prior history of stroke or transient ischaemic attacks. Caution should be exercised when treating such patients (see section 4.8).

4.5 Interaction with other medicinal products and other forms of interaction

No formal interaction studies have been performed.

For the adjunctive use of verteporfin photodynamic therapy (PDT) and ranibizumab in wet AMD and PM, see section 5.1.

For the adjunctive use of laser photocoagulation and ranibizumab in DME and BRVO, see sections 4.2 and 5.1.

In clinical studies for the treatment of visual impairment due to DME, the outcome with regard to visual acuity or central retinal subfield thickness (CSFT) in patients treated with ranibizumab was not affected by concomitant treatment with thiazolidinediones.

4.6 Fertility, pregnancy and lactation

Women of childbearing potential/contraception in females

Women of childbearing potential should use effective contraception during treatment.

Pregnancy

For ranibizumab no clinical data on exposed pregnancies are available. Studies in cynomolgus monkeys do not indicate direct or indirect harmful effects with respect to pregnancy or embryonal/foetal development (see section 5.3). The systemic exposure to ranibizumab is low after ocular administration, but due to its mechanism of action, ranibizumab must be regarded as potentially teratogenic and embryo-/foetotoxic.

Therefore, ranibizumab should not be used during pregnancy unless the expected benefit outweighs the potential risk to the foetus. For women who wish to become pregnant and have been treated with ranibizumab, it is recommended to wait at least 3 months after the last dose of ranibizumab before conceiving a child.

Breast-feeding

Based on very limited data, ranibizumab may be excreted in human milk at low levels. The effect of ranibizumab on a breast-fed newborn/infant is unknown. As a precautionary measure, breast-feeding is not recommended during the use of ranibizumab.

Fertility

There are no data available on fertility.

4.7 Effects on ability to drive and use machines

The treatment procedure may induce temporary visual disturbances, which may affect the ability to drive or use machines (see section 4.8). Patients who experience these

signs must not drive or use machines until these temporary visual disturbances subside.

4.8 Undesirable effects

Summary of the safety profile

The majority of adverse reactions reported following administration of ranibizumab are related to the intravitreal injection procedure.

The most frequently reported ocular adverse reactions following injection of ranibizumab are: eye pain, ocular hyperaemia, increased intraocular pressure, vitritis, vitreous detachment, retinal haemorrhage, visual disturbance, vitreous floaters, conjunctival haemorrhage, eye irritation, foreign body sensation in eyes, increased lacrimation, blepharitis, dry eye and eye pruritus.

The most frequently reported non-ocular adverse reactions are headache, nasopharyngitis and arthralgia.

Less frequently reported, but more serious, adverse reactions include endophthalmitis, blindness, retinal detachment, retinal tear and iatrogenic traumatic cataract (see section 4.4).

The adverse reactions experienced following administration of ranibizumab in clinical trials are summarised in the table below.

Tabulated list of adverse reactions[#]

The adverse reactions are listed by system organ class and frequency using the following convention: very common ($\geq 1/10$), common ($\geq 1/100$ to $< 1/10$), uncommon ($\geq 1/1,000$ to $< 1/100$), rare ($\geq 1/10,000$ to $< 1/1,000$), very rare ($< 1/10,000$), not known (cannot be estimated from the available data). Within each frequency grouping, adverse reactions are presented in order of decreasing seriousness.

Infections and infestations

Very common

Nasopharyngitis

Common

Urinary tract infection*

Blood and lymphatic system disorders

Common

Anaemia

Immune system disorders

Common

Hypersensitivity

Psychiatric disorders

Common

Anxiety

Nervous system disorders

Very common

Headache

Eye disorders

Very common

Vitritis, vitreous detachment, retinal haemorrhage, visual disturbance, eye pain, vitreous floaters, conjunctival haemorrhage, eye irritation, foreign body sensation in eyes, lacrimation increased, blepharitis, dry eye, ocular hyperaemia, eye pruritus.

Common

Retinal degeneration, retinal disorder, retinal detachment, retinal tear, detachment of the retinal pigment epithelium, retinal pigment epithelium tear, visual acuity reduced, vitreous haemorrhage, vitreous disorder, uveitis, iritis, iridocyclitis, cataract, cataract subcapsular, posterior capsule opacification, punctuate keratitis, corneal abrasion, anterior chamber flare, vision blurred, injection site haemorrhage, eye haemorrhage, conjunctivitis, conjunctivitis allergic, eye discharge, photopsia, photophobia, ocular discomfort, eyelid oedema, eyelid pain, conjunctival hyperaemia.

Uncommon

Blindness, endophthalmitis, hypopyon, hyphaema, keratopathy, iris adhesion, corneal deposits, corneal oedema, corneal striae, injection site pain, injection site irritation, abnormal sensation in eye, eyelid irritation.

Respiratory, thoracic and mediastinal disorders

Common

Cough

Gastrointestinal disorders

Common

Nausea

Skin and subcutaneous tissue disorders

Common

Allergic reactions (rash, urticaria, pruritus, erythema)

Musculoskeletal and connective tissue disorders

Very common

Arthralgia

Investigations

Very common

Intraocular pressure increased

Adverse reactions were defined as adverse events (in at least 0.5 percentage points of patients) which occurred at a higher rate (at least 2 percentage points) in patients receiving treatment with ranibizumab 0.5 mg than in those receiving control treatment (sham or verteporfin PDT).

* observed only in DME population

Product-class-related adverse reactions

In the wet AMD phase III studies, the overall frequency of non-ocular haemorrhages, an adverse event potentially related to systemic VEGF (vascular endothelial growth factor) inhibition, was slightly increased in ranibizumab-treated patients. However, there was no consistent pattern among the different haemorrhages. There is a theoretical risk of arterial thromboembolic events, including stroke and myocardial infarction, following intravitreal use of VEGF inhibitors. A low incidence rate of arterial thromboembolic events was observed in the ranibizumab clinical trials in patients with AMD, DME, PDR, RVO and CNV and there were no major differences between the groups treated with ranibizumab compared to control.

Reporting of suspected adverse reactions

Reporting suspected adverse reactions after authorisation of the medicinal product is important. It allows continued monitoring of the benefit/risk balance of the medicinal product. Healthcare professionals are asked to report any suspected adverse reactions via the Yellow Card Scheme at: www.mhra.gov.uk/yellowcard or search for MHRA Yellow Card in the Google Play or Apple App Store.

4.9 Overdose

Cases of accidental overdose have been reported from the clinical studies in wet AMD and post-marketing data. Adverse reactions associated with these reported cases were intraocular pressure increased, transient blindness, reduced visual acuity, corneal oedema, corneal pain, and eye pain. If an overdose occurs, intraocular pressure should be monitored and treated, if deemed necessary by the attending physician.

5 PHARMACOLOGICAL PROPERTIES

5.1 Pharmacodynamic properties

Pharmacotherapeutic group: Ophthalmologicals, antineovascularisation agents, ATC code: S01LA04

Byooviz is a biosimilar medicinal product.

Mechanism of action

Ranibizumab is a humanised recombinant monoclonal antibody fragment targeted against human vascular endothelial growth factor A (VEGF-A). It binds with high affinity to the VEGF-A isoforms (e.g. VEGF110, VEGF121 and VEGF165), thereby preventing binding of VEGF-A to its receptors VEGFR-1 and VEGFR-2. Binding of VEGF-A to its receptors leads to endothelial cell proliferation and neovascularisation, as well as vascular leakage, all of which are thought to contribute to the progression of the neovascular form of age-related macular degeneration, pathologic myopia and CNV or to visual impairment caused by either diabetic macular oedema or macular oedema secondary to RVO in adults.

Clinical efficacy and safety

Treatment of wet AMD

In wet AMD, the clinical safety and efficacy of ranibizumab have been assessed in three randomised, double-masked, sham- or active-controlled studies of 24 months duration in patients with neovascular AMD. A total of 1,323 patients (879 active and 444 control) were enrolled in these studies.

In study FVF2598g (MARINA), 716 patients with minimally classic or occult with no classic lesions were randomised in a 1:1:1 ratio to receive monthly injections of ranibizumab 0.3 mg, ranibizumab 0.5 mg or sham.

In study FVF2587g (ANCHOR), 423 patients with predominantly classic CNV lesions were randomised in a 1:1:1 ratio to receive ranibizumab 0.3 mg monthly, ranibizumab 0.5 mg monthly or verteporfin PDT (at baseline and every 3 months thereafter if fluorescein angiography showed persistence or recurrence of vascular leakage).

Key outcome measures are summarised in Table 1 and Figure 1.

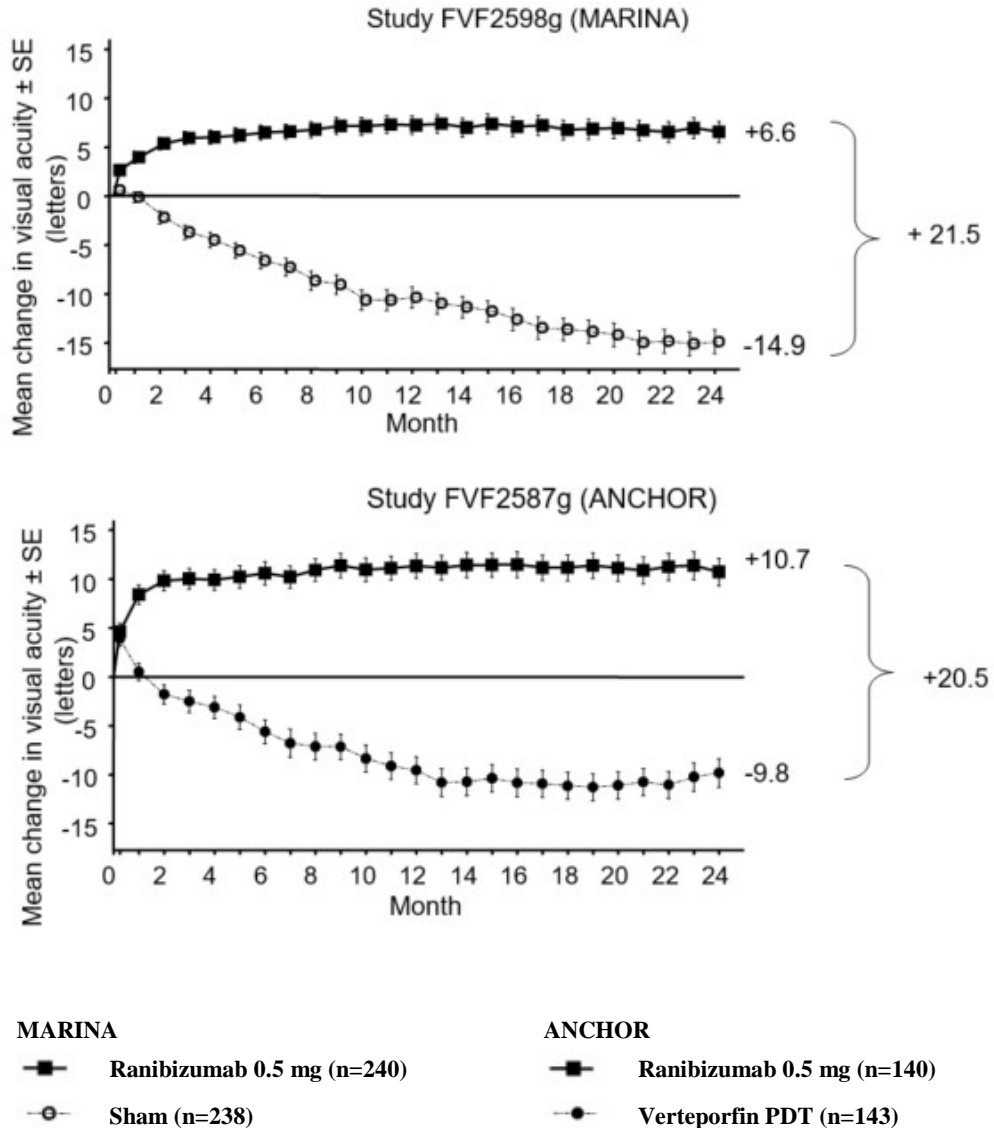
Table 1 Outcomes at Month 12 and Month 24 in study FVF2598g (MARINA) and FVF2587g (ANCHOR)

Outcome measure	Month	FVF2598g (MARINA)		FVF2587g (ANCHOR)	
		Sham (n=238)	Ranibizumab 0.5 mg (n=240)	Verteporfin PDT (n=143)	Ranibizumab 0.5 mg (n=140)
Loss of <15 letters in visual acuity (%) ^a (maintenance of vision, primary endpoint)	Month 12	62%	95%	64%	96%
	Month 24	53%	90%	66%	90%

Gain of ≥ 15 letters in visual acuity (%) ^a	Month 12	5%	34%	6%	40%
	Month 24	4%	33%	6%	41%
Mean change in visual acuity (letters) (SD) ^a	Month 12	-10.5 (16.6)	+7.2 (14.4)	-9.5 (16.4)	+11.3 (14.6)
	Month 24	-14.9 (18.7)	+6.6 (16.5)	-9.8 (17.6)	+10.7 (16.5)

^a p<0.01

Figure 1 Mean change in visual acuity from baseline to Month 24 in study FVF2598g (MARINA) and study FVF2587g (ANCHOR)



Results from both trials indicated that continued ranibizumab treatment may also be of benefit in patients who lost ≥ 15 letters of best-corrected visual acuity (BCVA) in the first year of treatment.

Statistically significant patient-reported visual functioning benefits were observed in both MARINA and ANCHOR with ranibizumab treatment over the control group as measured by the NEI VFQ-25.

In study FVF3192g (PIER), 184 patients with all forms of neovascular AMD were randomised in a 1:1:1 ratio to receive ranibizumab 0.3 mg, ranibizumab 0.5 mg or sham injections once a month for 3 consecutive doses, followed by a dose administered once every 3 months. From Month 14 of the study, sham-

treated patients were allowed to receive ranibizumab and from Month 19, more frequent treatments were possible. Patients treated with ranibizumab in PIER received a mean of 10 total treatments.

After an initial increase in visual acuity (following monthly dosing), on average, patients’ visual acuity declined with quarterly dosing, returning to baseline at Month 12 and this effect was maintained in most ranibizumab-treated patients (82%) at Month 24. Limited data from sham subjects who later received ranibizumab suggested that early initiation of treatment may be associated with better preservation of visual acuity.

Data from two studies (MONT BLANC, BPD952A2308 and DENALI, BPD952A2309) conducted post approval confirmed the efficacy of ranibizumab but did not demonstrate additional effect of the combined administration of verteporfin (Visudyne PDT) and ranibizumab compared to ranibizumab monotherapy.

Treatment of visual impairment due to CNV secondary to PM

The clinical safety and efficacy of ranibizumab in patients with visual impairment due to CNV in PM have been assessed based on the 12-month data of the double-masked, controlled pivotal study F2301 (RADIANCE). In this study 277 patients were randomised in a 2:2:1 ratio to the following arms:

- Group I (ranibizumab 0.5 mg, dosing regimen driven by “stability” criteria defined as no change in BCVA compared to two preceding monthly evaluations).
- Group II (ranibizumab 0.5 mg, dosing regimen driven by “disease activity” criteria defined as vision impairment attributable to intra- or subretinal fluid or active leakage due to the CNV lesion as assessed by optical coherence tomography and/or fluorescence angiography).
- Group III (vPDT - patients were allowed to receive ranibizumab treatment as of Month 3).

In Group II, which is the recommended posology (see section 4.2), 50.9% of patients required 1 or 2 injections, 34.5% required 3 to 5 injections and 14.7% required 6 to 12 injections over the 12-month study period. 62.9% of Group II patients did not require injections in the second 6 months of the study.

The key outcomes from RADIANCE are summarised in Table 2 and Figure 2.

Table 2 Outcomes at Month 3 and 12 (RADIANCE)

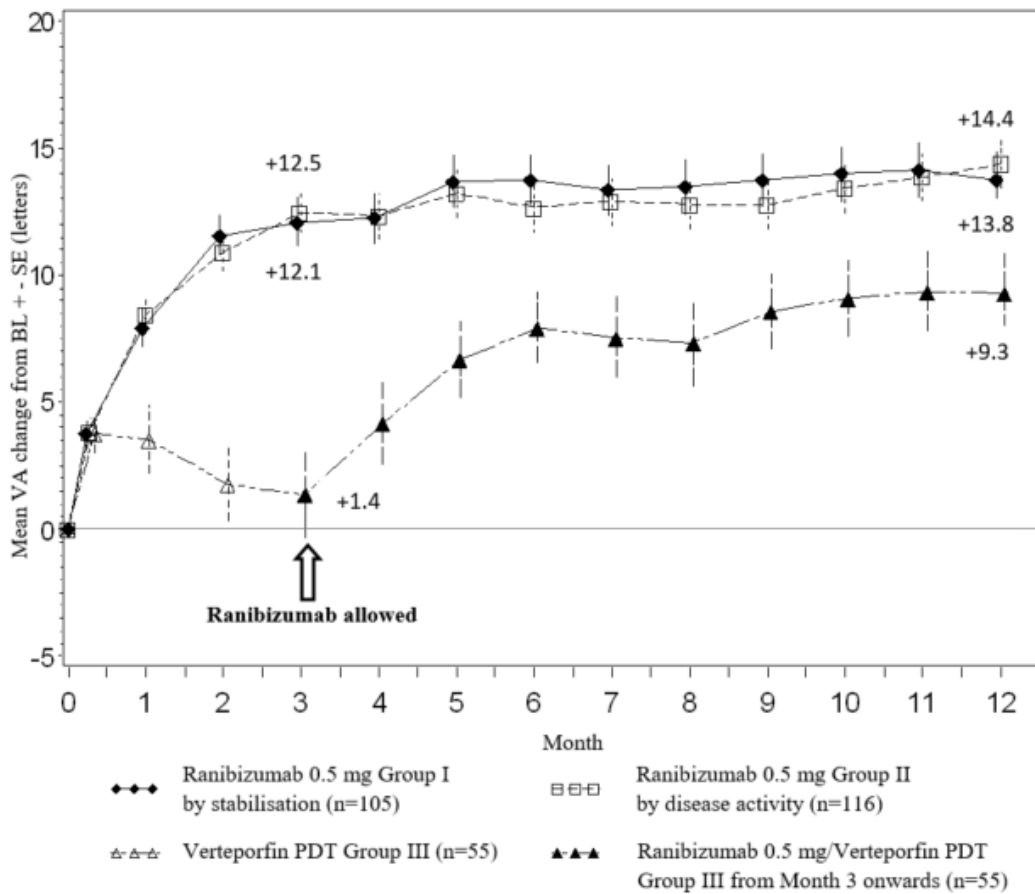
	Group I	Group II	Group III
	Ranibizuma	Ranibizuma	vPDT^b
	b	b	
	0.5 mg	0.5 mg	
	“vision	“disease	

	stability” (n=105)	activity” (n=116)	(n=55)
Month 3			
Mean average BCVA change from Month 1 to Month 3 compared to baseline ^a (letters)	+10.5	+10.6	+2.2
Proportion of patients who gained: ≥ 15 letters, or reached ≥ 84 letters in BCVA	38.1%	43.1%	14.5%
Month 12			
Number of injections up to Month 12:			
Mean	4.6	3.5	N/A
Median	4.0	2.5	N/A
Mean average BCVA change from Month 1 to Month 12 compared to baseline (letters)	+12.8	+12.5	N/A
Proportion of patients who gained: ≥ 15 letters, or reached ≥ 84 letters in BCVA	53.3%	51.7%	N/A

^a $p < 0.00001$ comparison with vPDT control

^b Comparative control up to Month 3. Patients randomised to vPDT were allowed to receive ranibizumab treatment as of Month 3 (in Group III, 38 patients received ranibizumab as of Month 3)

Figure 2 Mean change from baseline BCVA over time to Month 12 (RADIANCE)



The improvement of vision was accompanied by a reduction in central retinal thickness.

Patient-reported benefits were observed with ranibizumab treatment arms over vPDT (p-value <0.05) in terms of improvement in the composite score and several subscales (general vision, near activities, mental health and dependency) of the NEI VFQ-25.

Treatment of visual impairment due to CNV (other than secondary to PM and wet AMD)

The clinical safety and efficacy of ranibizumab in patients with visual impairment due to CNV have been assessed based on the 12-month data of the double-masked, sham-controlled pivotal study G2301 (MINERVA). In this study 178 adult patients were randomised in a 2:1 ratio to receive:

- ranibizumab 0.5 mg at baseline, followed by an individualised dosing regimen driven by disease activity as assessed by visual acuity and/or anatomical parameters (e.g. VA impairment, intra/sub-retinal fluid, haemorrhage or leakage);

- sham injection at baseline, followed by an individualised treatment regimen driven by disease activity.

At Month 2, all patients received open-label treatment with ranibizumab as needed.

Key outcome measures from MINERVA are summarised in Table 3 and Figure 3. An improvement of vision was observed and was accompanied by a reduction in central subfield thickness over the 12-month period.

The mean number of injections given over 12 months was 5.8 in the ranibizumab arm versus 5.4 in those patients in the sham arm who were eligible to receive ranibizumab from Month 2 onwards. In the sham arm 7 out of 59 patients did not receive any treatment with ranibizumab in the study eye during the 12-month period.

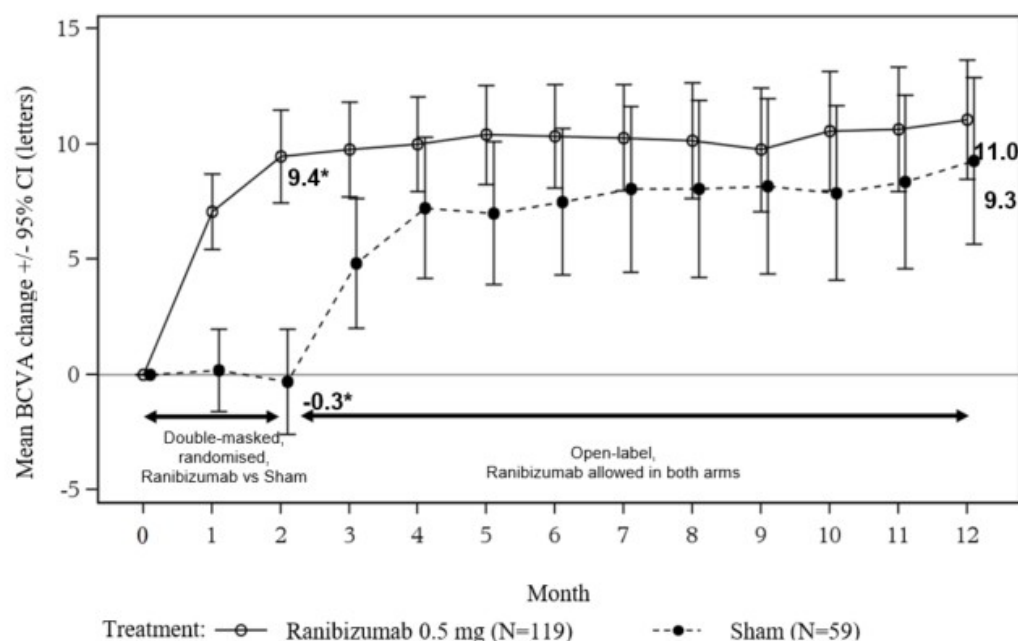
Table 3 Outcomes at Month 2 (MINERVA)

	Ranibizumab 0.5 mg (n=119)	Sham (n=59)
Mean BCVA change from baseline to Month 2 ^a	9.5 letters	-0.4 letters
Patients gaining ≥ 15 letters from baseline or reaching 84 letters at Month 2	31.4%	12.3%
Patients not losing >15 letters from baseline at Month 2	99.2%	94.7%
Reduction in CSFT ^b from baseline to Month 2 ^a	77 μm	-9.8 μm

^a One-sided $p < 0.001$ comparison with sham control

^b CSFT - central retinal subfield thickness

Figure 3 Mean change from baseline BCVA over time to Month 12 (MINERVA)



* Observed mean BCVA may differ from the Least Squares Mean BCVA (applicable only at Month 2)

When comparing ranibizumab versus sham control at Month 2, a consistent treatment effect both overall and across baseline aetiology subgroups was observed:

Table 4 Treatment effect overall and across baseline aetiology subgroups

Overall and per baseline aetiology	Treatment effect over sham [letters]	Patient numbers [n] (treatment +sham)
Overall	9.9	178
Angioid streaks	14.6	27
Post-inflammatory retinochoroidopathy	6.5	28
Central serous chorioretinopathy	5.0	23
Idiopathic chorioretinopathy	11.4	63
Miscellaneous aetiologies ^a	10.6	37

^a encompasses different aetiologies of low frequency of occurrence not included in the other subgroups

In the pivotal study G2301 (MINERVA), five adolescent patients aged 12 to 17 years with visual impairment secondary to CNV received open-label treatment with ranibizumab 0.5 mg at baseline followed by an individualised treatment regimen as for the adult population. BCVA improved from baseline to Month 12 in all five patients, ranging from 5 to 38 letters (mean of

16.6 letters). The improvement of vision was accompanied by a stabilisation or reduction in central subfield thickness over the 12-month period. The mean number of ranibizumab injections given in the study eye over 12 months was 3 (ranged from 2 to 5). Overall, ranibizumab treatment was well tolerated.

Treatment of visual impairment due to DME

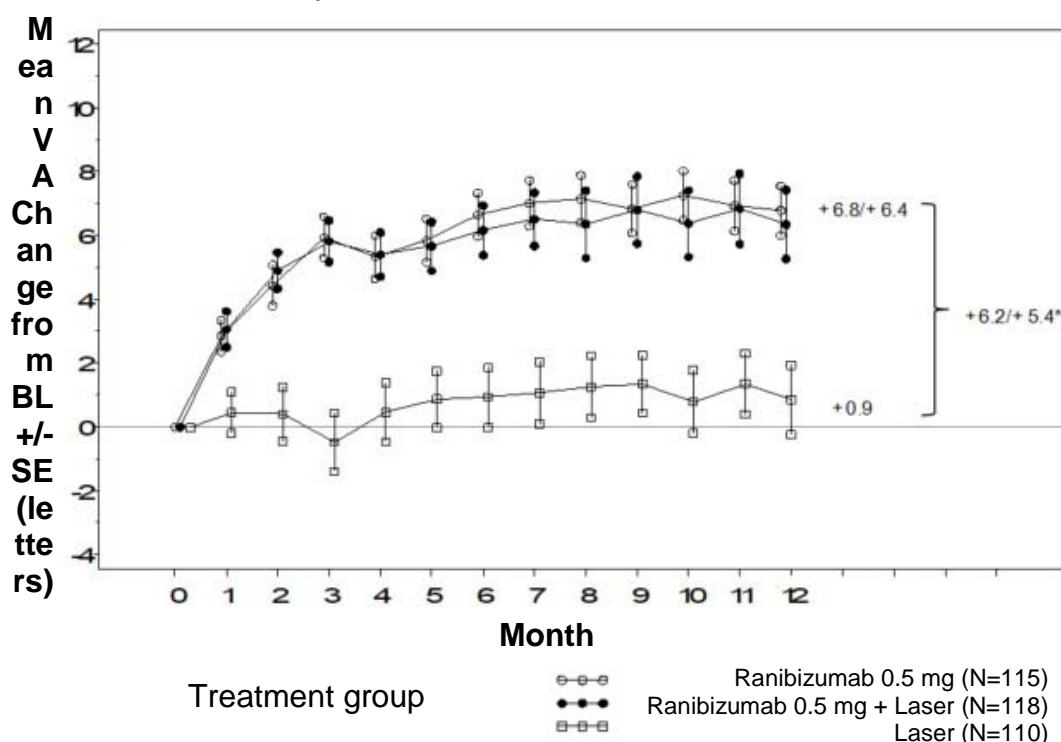
The efficacy and safety of ranibizumab have been assessed in three randomised, controlled studies of at least 12 months duration. A total of 868 patients (708 active and 160 control) were enrolled in these studies.

In the phase II study D2201 (RESOLVE), 151 patients were treated with ranibizumab (6 mg/ml, n=51, 10 mg/ml, n=51) or sham (n=49) by monthly intravitreal injections. The mean average change in BCVA from Month 1 to Month 12 compared to baseline was +7.8 (± 7.72) letters in the pooled ranibizumab-treated patients (n=102), compared to -0.1 (± 9.77) letters for sham-treated patients; and the mean change in BCVA at Month 12 from baseline was 10.3 (± 9.1) letters compared to -1.4 (± 14.2) letters, respectively (p<0.0001 for the treatment difference).

In the phase III study D2301 (RESTORE), 345 patients were randomised in a 1:1:1 ratio to receive ranibizumab 0.5 mg monotherapy and sham laser photocoagulation, combined ranibizumab 0.5 mg and laser photocoagulation or sham injection and laser photocoagulation. 240 patients, who had previously completed the 12-month RESTORE study, were enrolled in the open-label, multicentre 24-month extension (RESTORE Extension) study. Patients were treated with ranibizumab 0.5 mg *pro re nata* (PRN) in the same eye as the core study (D2301 RESTORE).

Key outcome measures are summarised in Table 5 (RESTORE and Extension) and Figure 4 (RESTORE).

Figure 4 Mean change in visual acuity from baseline over time in study D2301 (RESTORE)



BL=baseline; SE=standard error of mean

* Difference in least square means, $p < 0.0001/0.0004$ based on two-sided stratified Cochran-Mantel-Haenszel test

The effect at 12 months was consistent in most subgroups. However, subjects with a baseline BCVA >73 letters and macular oedema with central retinal thickness $<300 \mu\text{m}$ did not appear to benefit from treatment with ranibizumab compared to laser photocoagulation.

Table 5 Outcomes at Month 12 in study D2301 (RESTORE) and at Month 36 in study D2301-E1 (RESTORE Extension)

Outcome measures at Month 12 compared to baseline in study D2301 (RESTORE)	Ranibizumab 0.5 mg n=115	Ranibizumab 0.5 mg + Laser n=118	Laser n=110
Mean average change in BCVA from Month 1 to Month 12 ^a (\pm SD)	6.1 (6.4) ^a	5.9 (7.9) ^a	0.8 (8.6)
Mean change in BCVA at Month 12 (\pm SD)	6.8 (8.3) ^a	6.4 (11.8) ^a	0.9 (11.4)
Gain of ≥ 15 letters or BCVA ≥ 84 letters at Month 12 (%)	22.6	22.9	8.2
Mean number of injections (Months 0-11)	7.0	6.8	7.3 (sham)

Outcome measure at Month 36 compared to D2301 (RESTORE) baseline in study D2301-E1 (RESTORE Extension)	Prior ranibizumab 0.5 mg n=83	Prior ranibizumab 0.5 mg + laser n=83	Prior laser n=74
Mean change in BCVA at Month 24 (SD)	7.9 (9.0)	6.7 (7.9)	5.4 (9.0)
Mean change in BCVA at Month 36 (SD)	8.0 (10.1)	6.7 (9.6)	6.0 (9.4)
Gain of ≥ 15 letters or BCVA ≥ 84 letters at Month 36 (%)	27.7	30.1	21.6
Mean number of injections (Months 12-35)*	6.8	6.0	6.5

^a p<0.0001 for comparisons of ranibizumab arms vs. laser arm.

n in D2301-E1 (RESTORE Extension) is the number of patients with a value at both D2301 (RESTORE) baseline (Month 0) and at the Month 36 visit.

* The proportion of patients who did not require any ranibizumab treatment during the extension phase was 19%, 25% and 20% in the prior ranibizumab, prior ranibizumab + laser and prior laser groups, respectively.

Statistically significant patient-reported benefits for most vision-related functions were observed with ranibizumab (with or without laser) treatment over the control group as measured by the NEI VFQ-25. For other subscales of this questionnaire no treatment differences could be established.

The long-term safety profile of ranibizumab observed in the 24-month extension study is consistent with the known ranibizumab safety profile.

In the phase IIIb study D2304 (RETAIN), 372 patients were randomised in 1:1:1 ratio to receive:

- ranibizumab 0.5 mg with concomitant laser photocoagulation on a treat-and-extend (TE) regimen,
- ranibizumab 0.5 mg monotherapy on a TE regimen,
- ranibizumab 0.5 mg monotherapy on a PRN regimen.

In all groups, ranibizumab was administered monthly until BCVA was stable for at least three consecutive monthly assessments. On TE, ranibizumab was administered at treatment intervals of 2-3 months. In all groups, monthly treatment was re-initiated upon a decrease in BCVA due to DME progression and continued until stable BCVA was reached again.

The number of scheduled treatment visits after the initial 3 injections, was 13 and 20 for the TE and PRN regimens, respectively. With both TE regimens, more than 70% of patients maintained their BCVA with an average visit frequency of ≥ 2 months.

The key outcome measures are summarised in Table 6.

Table 6 Outcomes in study D2304 (RETAIN)

Outcome measure compared to baseline	TE ranibizumab 0.5 mg + laser n=117	TE ranibizumab 0.5 mg alone n=125	PRN ranibizumab 0.5 mg n=117
Mean average change in BCVA from Month 1 to Month 12 (SD)	5.9 (5.5) ^a	6.1 (5.7) ^a	6.2 (6.0)
Mean average change in BCVA from Month 1 to Month 24 (SD)	6.8 (6.0)	6.6 (7.1)	7.0 (6.4)
Mean change in BCVA at Month 24 (SD)	8.3 (8.1)	6.5 (10.9)	8.1 (8.5)
Gain of ≥15 letters or BCVA ≥84 letters at Month 24 (%)	25.6	28.0	30.8
Mean number of injections (months 0-23)	12.4	12.8	10.7

^ap<0.0001 for assessment of non-inferiority to PRN

In DME studies, the improvement in BCVA was accompanied by a reduction over time in mean CSFT in all the treatment groups.

Treatment of PDR

The clinical safety and efficacy of ranibizumab in patients with PDR have been assessed in Protocol S which evaluated the treatment with ranibizumab 0.5 mg intravitreal injections compared with panretinal photocoagulation (PRP). The primary endpoint was the mean visual acuity change at year 2. Additionally, change in diabetic retinopathy (DR) severity was assessed based on fundus photographs using the DR severity score (DRSS).

Protocol S was a multicentre, randomised, active-controlled, parallel-assignment, non-inferiority phase III study in which 305 patients (394 study eyes) with PDR with or without DME at baseline were enrolled. The study compared ranibizumab 0.5 mg intravitreal injections to standard treatment with PRP. A total of 191 eyes (48.5%) were randomised to ranibizumab 0.5 mg and 203 eyes (51.5%) eyes were randomised to PRP. A total of 88 eyes (22.3%) had baseline DME: 42 (22.0%) and 46 (22.7%) eyes in the ranibizumab and PRP groups, respectively.

In this study, the mean visual acuity change at year 2 was +2.7 letters in the ranibizumab group compared to -0.7 letters in the PRP group. The difference in least square means was 3.5 letters (95% CI: [0.2 to 6.7]).

At year 1, 41.8% of eyes experienced a ≥ 2 -step improvement in the DRSS when treated with ranibizumab (n=189) compared to 14.6% of eyes treated with PRP (n=199). The estimated difference between ranibizumab and laser was 27.4% (95% CI: [18.9, 35.9]).

Table 7 DRSS improvement or worsening of ≥ 2 or ≥ 3 steps at year 1 in Protocol S (LOCF Method)

Categorised change from baseline	Protocol S		
	Ranibizumab 0.5 mg (N=189)	PRP (N=199)	Difference in proportion (%), CI
≥ 2 -step improvement			
n (%)	79 (41.8%)	29 (14.6%)	27.4 (18.9, 35.9)
≥ 3 -step improvement			
n (%)	54 (28.6%)	6 (3.0%)	25.7 (18.9, 32.6)
≥ 2 -step worsening			
n (%)	3 (1.6%)	23 (11.6%)	-9.9 (-14.7, -5.2)
≥ 3 -step worsening			
n (%)	1 (0.5%)	8 (4.0%)	-3.4 (-6.3, -0.5)
DRSS = diabetic retinopathy severity score, n = number of patients who satisfied the condition at the visit, N = total number of study eyes.			

At year 1 in the ranibizumab-treated group in Protocol S, ≥ 2 -step improvement in DRSS was consistent in eyes without DME (39.9%) and with baseline DME (48.8%).

An analysis of year 2 data from Protocol S demonstrated that 42.3% (n=80) of eyes in the ranibizumab-treated group had ≥ 2 -step improvement in DRSS from baseline compared with 23.1% (n=46) of eyes in the PRP group. In the ranibizumab-treated group, ≥ 2 -step improvement in DRSS from baseline was observed in 58.5% (n=24) of eyes with baseline DME and 37.8% (n=56) of eyes without DME.

DRSS was also assessed in three separate active-controlled phase III DME studies (ranibizumab 0.5 mg PRN vs laser) that included a total of 875 patients, of whom approximately 75% were of Asian origin. In a meta-analysis of these studies, 48.4% of the 315 patients with gradable DRSS scores in the subgroup of patients with moderately severe non-proliferative DR (NPDR) or

worse at baseline experienced a ≥ 2 -step improvement in the DRSS at Month 12 when treated with ranibizumab (n=192) vs 14.6% of patients treated with laser (n=123). The estimated difference between ranibizumab and laser was 29.9% (95% CI: [20.0, 39.7]). In the 405 DRSS gradable patients with moderate NPDR or better, a ≥ 2 -step DRSS improvement was observed in 1.4% and 0.9% of the ranibizumab and laser groups, respectively.

Treatment of visual impairment due to macular oedema secondary to RVO

The clinical safety and efficacy of ranibizumab in patients with visual impairment due to macular oedema secondary to RVO have been assessed in the randomised, double-masked, controlled studies BRAVO and CRUISE that recruited subjects with BRVO (n=397) and CRVO (n=392), respectively. In both studies, subjects received either 0.3 mg or 0.5 mg ranibizumab or sham injections. After 6 months, patients in the sham-control arms switched to 0.5 mg ranibizumab.

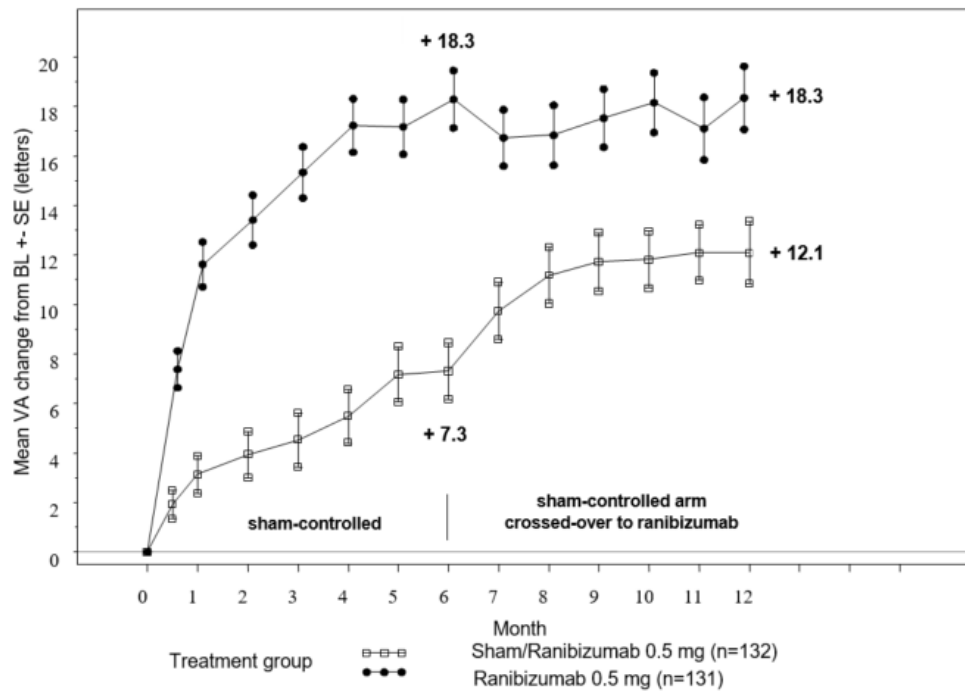
Key outcome measures from BRAVO and CRUISE are summarised in Table 8 and Figures 5 and 6.

Table 8 Outcomes at Month 6 and 12 (BRAVO and CRUISE)

	BRAVO		CRUISE	
	Sham/ Ranibizumab 0.5 mg (n=132)	Ranibizumab b 0.5 mg (n=131)	Sham/ Ranibizumab 0.5 mg (n=130)	Ranibizumab 0.5 mg (n=130)
Mean change in visual acuity at Month 6 ^a (letters) (SD) (primary endpoint)	7.3 (13.0)	18.3 (13.2)	0.8 (16.2)	14.9 (13.2)
Mean change in BCVA at Month 12 (letters) (SD)	12.1 (14.4)	18.3 (14.6)	7.3 (15.9)	13.9 (14.2)
Gain of ≥ 15 letters in visual acuity at Month 6 ^a (%)	28.8	61.1	16.9	47.7
Gain of ≥ 15 letters in visual acuity at Month 12 (%)	43.9	60.3	33.1	50.8
Proportion (%) receiving laser rescue over 12 months	61.4	34.4	NA	NA

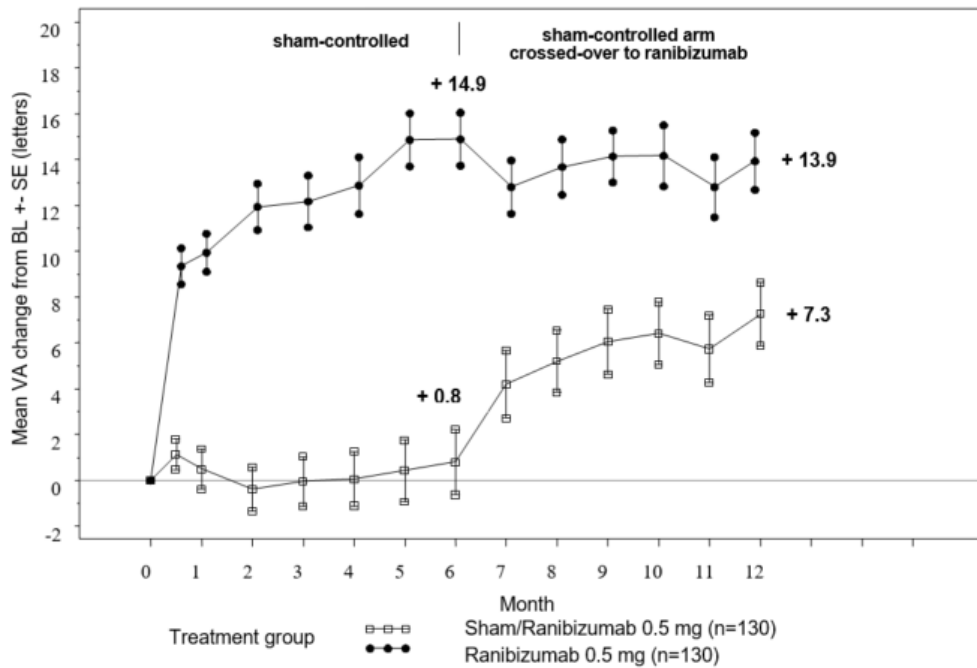
^a p<0.0001 for both studies

Figure 5 Mean change from baseline BCVA over time to Month 6 and Month 12 (BRAVO)



BL=baseline; SE=standard error of mean

Figure 6 Mean change from baseline BCVA over time to Month 6 and Month 12 (CRUISE)



BL=baseline; SE=standard error of mean

In both studies, the improvement of vision was accompanied by a continuous and significant reduction in the macular oedema as measured by central retinal thickness.

In patients with CRVO (CRUISE and extension study HORIZON): Subjects treated with sham in the first 6 months who subsequently received ranibizumab did not achieve comparable gains in VA by Month 24 (~6 letters) compared to subjects treated with ranibizumab from study start (~12 letters).

Statistically significant patient-reported benefits in subscales related to near and distance activity were observed with ranibizumab treatment over the control group as measured by the NEI VFQ-25.

The long-term (24 months) clinical safety and efficacy of ranibizumab in patients with visual impairment due to macular oedema secondary to RVO were assessed in the BRIGHTER (BRVO) and CRYSTAL (CRVO) studies. In both studies, subjects received a 0.5 mg ranibizumab PRN dosing regimen driven by individualised stabilisation criteria. BRIGHTER was a 3-arm randomised active-controlled study that compared 0.5 mg ranibizumab given as monotherapy or in combination with adjunctive laser photocoagulation to laser photocoagulation alone. After 6 months, subjects in the laser arm could receive 0.5 mg ranibizumab. CRYSTAL was a single-arm study with 0.5 mg ranibizumab monotherapy.

Key outcome measures from BRIGHTER and CRYSTAL are shown in Table 9.

Table 9 Outcomes at Months 6 and 24 (BRIGHTER and CRYSTAL)

	BRIGHTER			CRYSTAL
	Ranibizumab 0.5 mg N=180	Ranibizumab 0.5 mg + Laser N=178	Laser* N=90	Ranibizumab 0.5 mg N=356
Mean change in BCVA at Month 6 ^a (letters) (SD)	+14.8 (10.7)	+14.8 (11.13)	+6.0 (14.27)	+12.0 (13.95)
Mean change in BCVA at Month 24 ^b (letters) (SD)	+15.5 (13.91)	+17.3 (12.61)	+11.6 (16.09)	+12.1 (18.60)
Gain of ≥15 letters in BCVA at Month 24 (%)	52.8	59.6	43.3	49.2
Mean number of injections (SD) (Months 0-23)	11.4 (5.81)	11.3 (6.02)	NA	13.1 (6.39)
^a	p<0.0001 for both comparisons in BRIGHTER at Month 6: Ranibizumab			

b	0.5 mg vs Laser and Ranibizumab 0.5 mg + Laser vs Laser. p<0.0001 for null hypothesis in CRYSTAL that the mean change at Month 24 from baseline is zero.
*	Starting at Month 6 ranibizumab 0.5 mg treatment was allowed (24 patients were treated with laser only).

In BRIGHTER, ranibizumab 0.5 mg with adjunctive laser therapy demonstrated non-inferiority versus ranibizumab monotherapy from baseline to Month 24 (95% CI -2.8, 1.4).

In both studies, a rapid and statistically significant decrease from baseline in central retinal subfield thickness was observed at Month 1. This effect was maintained up to Month 24.

The effect of ranibizumab treatment was similar irrespective of the presence of retinal ischaemia. In BRIGHTER, patients with ischaemia present (N=46) or absent (N=133) and treated with ranibizumab monotherapy had a mean change from baseline of +15.3 and +15.6 letters, respectively, at Month 24. In CRYSTAL, patients with ischaemia present (N=53) or absent (N=300) and treated with ranibizumab monotherapy had a mean change from baseline of +15.0 and +11.5 letters, respectively.

The effect in terms of visual improvement was observed in all patients treated with 0.5 mg ranibizumab monotherapy regardless of their disease duration in both BRIGHTER and CRYSTAL. In patients with <3 months disease duration an increase in visual acuity of 13.3 and 10.0 letters was seen at Month 1; and 17.7 and 13.2 letters at Month 24 in BRIGHTER and CRYSTAL, respectively. The corresponding visual acuity gain in patients with ≥12 months disease duration was 8.6 and 8.4 letters in the respective studies. Treatment initiation at the time of diagnosis should be considered.

The long-term safety profile of ranibizumab observed in the 24-month studies is consistent with the known ranibizumab safety profile.

Paediatric population

The European Medicines Agency has waived the obligation to submit the results of studies with ranibizumab in all subsets of the paediatric population in neovascular AMD, visual impairment due to DME, visual impairment due to macular oedema secondary to RVO and visual impairment due to CNV and diabetic retinopathy (see section 4.2 for information on paediatric use).

5.2 Pharmacokinetic properties

Following monthly intravitreal administration of ranibizumab to patients with neovascular AMD, serum concentrations of ranibizumab were generally low, with maximum levels (C_{max}) generally below the ranibizumab concentration necessary to inhibit the biological activity of VEGF by 50% (11-27 ng/ml, as assessed in an *in vitro* cellular proliferation assay). C_{max} was dose proportional over the dose range of 0.05 to 1.0 mg/eye. Serum concentrations in a limited number of DME patients indicate that a slightly higher systemic exposure cannot be excluded compared to those observed in neovascular AMD patients. Serum ranibizumab concentrations in RVO patients were similar or slightly higher compared to those observed in neovascular AMD patients.

Based on analysis of population pharmacokinetics and disappearance of ranibizumab from serum for patients with neovascular AMD treated with the 0.5 mg dose, the average vitreous elimination half-life of ranibizumab is approximately 9 days. Upon monthly intravitreal administration of ranibizumab 0.5 mg/eye, serum ranibizumab C_{max} , attained approximately 1 day after dosing, is predicted to generally range between 0.79 and 2.90 ng/ml, and C_{min} is predicted to generally range between 0.07 and 0.49 ng/ml. Serum ranibizumab concentrations are predicted to be approximately 90,000-fold lower than vitreal ranibizumab concentrations.

Patients with renal impairment: No formal studies have been conducted to examine the pharmacokinetics of ranibizumab in patients with renal impairment. In a population pharmacokinetic analysis of neovascular AMD patients, 68% (136 of 200) of patients had renal impairment (46.5% mild [50-80 ml/min], 20% moderate [30-50 ml/min], and 1.5% severe [<30 ml/min]). In RVO patients, 48.2% (253 of 525) had renal impairment (36.4% mild, 9.5% moderate and 2.3% severe). Systemic clearance was slightly lower, but this was not clinically significant.

Hepatic impairment: No formal studies have been conducted to examine the pharmacokinetics of ranibizumab in patients with hepatic impairment.

5.3 Preclinical safety data

Bilateral intravitreal administration of ranibizumab to cynomolgus monkeys at doses between 0.25 mg/eye and 2.0 mg/eye once every 2 weeks for up to 26 weeks resulted in dose-dependent ocular effects.

Intraocularly, there were dose-dependent increases in anterior chamber flare and cells with a peak 2 days after injection. The severity of the inflammatory response generally diminished with subsequent injections or during recovery. In the posterior segment, there were vitreal cell infiltration and floaters, which also tended to be dose-dependent and generally persisted to the end of the treatment period. In the 26-week study, the severity of the vitreous inflammation increased with the number of injections. However, evidence of reversibility was observed after recovery. The nature and timing of the posterior segment inflammation is suggestive of an immune-mediated antibody response, which may be clinically irrelevant. Cataract formation was observed in some animals after a relatively long period of intense inflammation,

suggesting that the lens changes were secondary to severe inflammation. A transient increase in post-dose intraocular pressure was observed following intravitreal injections, irrespective of dose.

Microscopic ocular changes were related to inflammation and did not indicate degenerative processes. Granulomatous inflammatory changes were noted in the optic disc of some eyes. These posterior segment changes diminished, and in some instances resolved, during the recovery period.

Following intravitreal administration, no signs of systemic toxicity were detected. Serum and vitreous antibodies to ranibizumab were found in a subset of treated animals.

No carcinogenicity or mutagenicity data are available.

In pregnant monkeys, intravitreal ranibizumab treatment resulting in maximal systemic exposures 0.9-7-fold a worst case clinical exposure did not elicit developmental toxicity or teratogenicity, and had no effect on weight or structure of the placenta, although, based on its pharmacological effect ranibizumab should be regarded as potentially teratogenic and embryo-/foetotoxic.

The absence of ranibizumab-mediated effects on embryo-foetal development is plausibly related mainly to the inability of the Fab fragment to cross the placenta. Nevertheless, a case was described with high maternal ranibizumab serum levels and presence of ranibizumab in foetal serum, suggesting that the anti-ranibizumab antibody acted as (Fc region containing) carrier protein for ranibizumab, thereby decreasing its maternal serum clearance and enabling its placental transfer. As the embryo- foetal development investigations were performed in healthy pregnant animals and disease (such as diabetes) may modify the permeability of the placenta towards a Fab fragment, the study should be interpreted with caution.

6 PHARMACEUTICAL PARTICULARS

6.1 List of excipients

α,α -trehalose dihydrate

Histidine hydrochloride, monohydrate

Histidine

Polysorbate 20 (E 432)

Water for injections

6.2 Incompatibilities

In the absence of compatibility studies, this medicinal product must not be mixed with other medicinal products.

6.3 Shelf life

26 months

6.4 Special precautions for storage

Store in a refrigerator (2°C - 8°C). Do not freeze.

Keep the pre-filled syringe in its sealed tray in the carton in order to protect from light.

Prior to use, the unopened tray may be stored at temperatures not exceeding 30°C for up to 1 week.

6.5 Nature and contents of container

0.165 ml sterile solution in a pre-filled syringe with a rubber plunger stopper, 0.05 ml molded translucent dose mark, and a twist off syringe cap with a tamper-evident rigid seal with a rubber tip cap including a Luer lock adapter. The pre-filled syringe is silicone oil-free, has a plunger rod and a finger grip, and is packed in a sealed tray.

Pack size of one pre-filled syringe.

6.6 Special precautions for disposal

The pre-filled syringe is sterile and is for single use only. Do not use the product if the packaging is damaged or has been tampered with.

To prepare Byooviz for intravitreal administration, please adhere to the instructions for use. Read all the instructions carefully before using the pre-filled syringe.

The opening of the sealed tray and all subsequent steps should be done under aseptic conditions, which includes the use of surgical hand disinfection, sterile gloves, a sterile drape and a sterile eyelid speculum (or equivalent) and the availability of sterile paracentesis (if required).

For the intravitreal injection, a 30-gauge x ½ inch sterile injection needle should be used (not provided).

Note: The 30-gauge x ½ inch sterile injection needle is not included in the package.

Note: The dose must be set to 0.05 ml.

The pre-filled syringe contains more than the recommended dose of 0.5 mg. The excess volume should be expelled prior to injection.

<p>Step 1: Prepare</p>	<ul style="list-style-type: none"> • Make sure that your pack contains a sterile pre-filled syringe in a sealed tray. • Keep the syringe in the sterile tray until ready for use. • Peel the lid off the syringe tray and, using aseptic technique, remove the syringe.
<p>Step 2: Inspect syringe</p>	<ul style="list-style-type: none"> • Byooviz should be colourless to pale yellow. • Do not use the pre-filled syringe if: <ul style="list-style-type: none"> - particulates, cloudiness, or discoloration are visible. - the syringe is damaged. - the syringe cap is not fully closed. - the gray rubber is visible in the transparent part of the syringe cap when holding the syringe vertically at eye level, indicating that the syringe has been tampered with. <p>Note: The plunger rod is completely or partially attached to the rubber stopper. Do not attempt to attach the plunger rod to the rubber stopper.</p>
<p>Step 3: Remove syringe cap</p>	<ul style="list-style-type: none"> • Twist off (do not pull or snap off) the syringe cap by holding the syringe in one hand and the syringe cap with the thumb and forefinger of the other hand.
<p>Step 4: Attach needle</p>	<ul style="list-style-type: none"> • Attach a 30 G x ½ inch sterile injection needle firmly onto the syringe by screwing it tightly onto the Luer lock. • Carefully remove the needle cap by pulling it straight off, when you are ready to administer Byooviz. <p>Note: Do not wipe the needle at any time.</p>
<p>Step 5: Dislodge air bubbles</p>	<ul style="list-style-type: none"> • Hold the syringe upright with the needle pointing up. • If there are any air bubbles, gently tap the syringe with your finger until the bubbles rise to the top. <p>Note: Do not pull back on the plunger rod at any time, to avoid compromising the sterility of the product.</p>
<p>Step 6: Expel air and adjust drug dose</p>	<ul style="list-style-type: none"> • Hold the syringe at eye level. • Look closely and locate the translucent dose mark. • Carefully push the plunger rod until the upper edge below the dome of the rubber stopper is aligned with the 0.05 ml translucent dose mark. • You may feel resistance when the rubber stopper contacts the dose mark. The resistance indicates the correct dosing volume of BYOOVIZ has been reached.
<p>Step 7: Inject</p>	<ul style="list-style-type: none"> • The injection procedure should be carried out under aseptic conditions. • Insert the needle into the injection site. • Inject slowly until rubber stopper reaches the bottom of the syringe to deliver the volume of 0.05 ml.

	<ul style="list-style-type: none"> • A different scleral site should be used for subsequent injections.
Step 8: Dispose	<p><i>Note: After injection, do not recap the needle or detach it from the syringe. This could lead to a needle stick injury.</i></p> <ul style="list-style-type: none"> • The pre-filled syringe is for single use only. Extraction of multiple doses from a pre-filled syringe may increase the risk of contamination and subsequent infection. • Dispose of any unused medicinal product or the used syringe together with the needle in accordance with local requirements or in a sharps disposal container.

7 MARKETING AUTHORISATION HOLDER

Samsung Bioepis UK Limited
5th floor
Profile West
950 Great West Road
Brentford
Middlesex TW8 9ES
United Kingdom

8 MARKETING AUTHORISATION NUMBER(S)

PL 45613/0040

9 DATE OF FIRST AUTHORISATION/RENEWAL OF THE AUTHORISATION

15/05/2026

10 DATE OF REVISION OF THE TEXT

15/05/2026